

Stereological characterization of individual acini using high-resolution X-ray tomographic microscopy

u^b
UNIVERSITÄT
BERN

PAUL SCHERRER INSTITUT
PSI

David Haberthür¹, Sébastien F. Barré², Stefan A. Tschanz², Marco Stampanoni^{1,3} and Johannes C. Schittny²

¹Swiss Light Source, Paul Scherrer Institute, Villigen, Switzerland,

²Institute of Anatomy, University of Bern, Switzerland, ³Institute of Biomedical Engineering, University and ETH Zürich, Switzerland

{barre,tschanz,schittny}@ana.unibe.ch,
{david.haberthuer,marco.stampanoni}@psi.ch

Introduction

THE pulmonary acinus (gas-exchange area which is ventilated by one purely conducting airway) represents the functional unit of the lung parenchyma. The difficulty to recognize the acini on two-dimensional physical sections leads to a limited knowledge about biological parameters like volume and surface. By using high-resolution tomographic microscopic imaging we were able to extract individual acini from rat lung samples to stereologically assess their individual volume and surface.

Materials and Methods

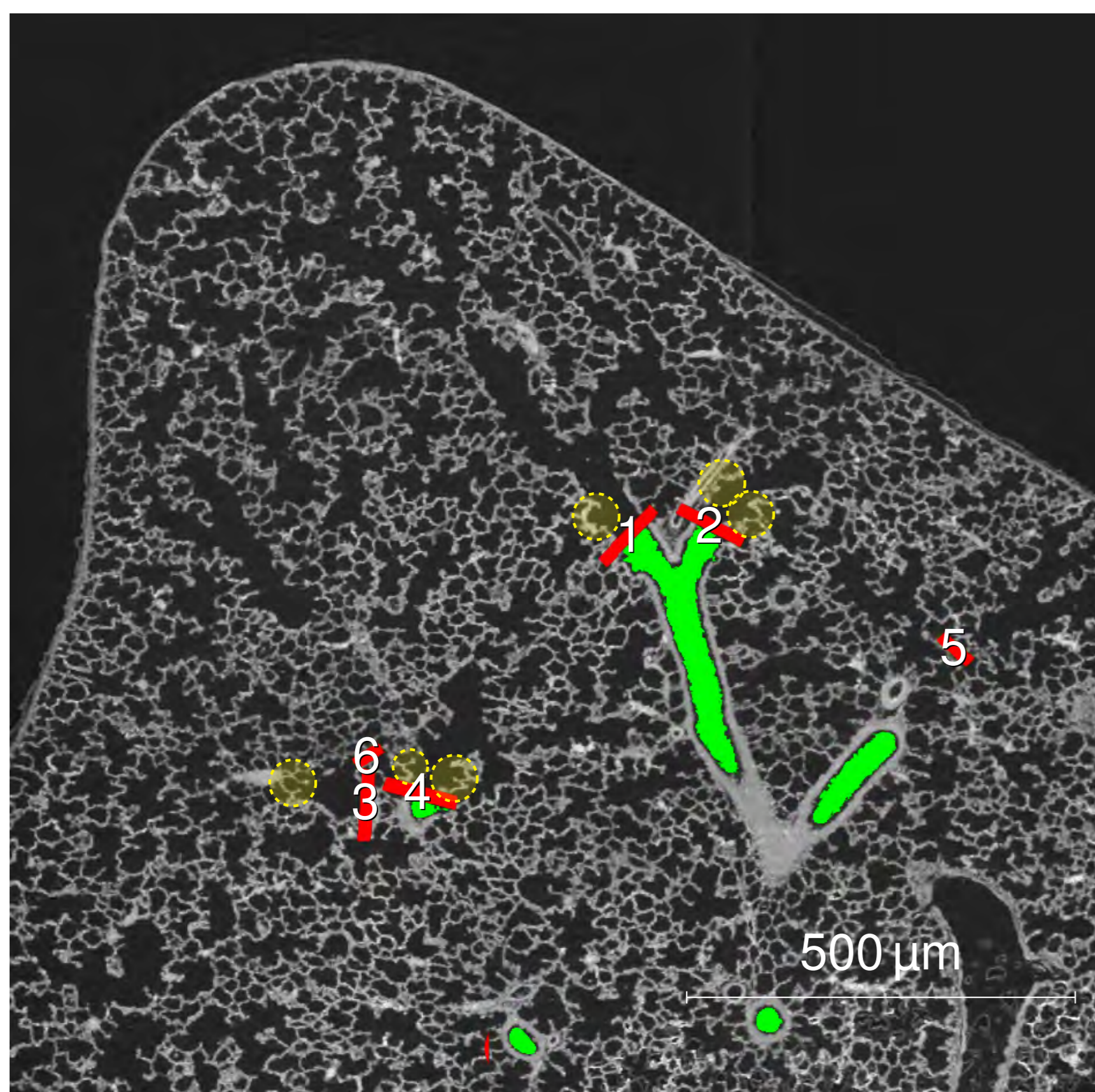


Figure 1: Sagittal slice of one tomographic dataset showing extracted conducting airways in green and several segmentation stoppers in red. The dashed yellow circles highlight some examples of alveoli which mark the change from conducting to gas-exchanging regions. Changes in thickness and structure of the epithelium and of the wall itself were also used to identify the entrances of the acini. Four segmentation stoppers (red) are shown cut right through the middle (1 to 4), two of them are only partially cut in this slice and thus appear much smaller (5 & 6).

LARGE, high-resolution (isotropic voxel size of 1.48 μm) tomographic datasets [1] of lung samples of three rats were recorded at the TOMCAT beamline at the Swiss Light Source in Villigen, Switzerland. In these tomographic datasets we isolated single acini by semi-automatically closing the transitory bronchioles at the transition from conducting to gas-exchanging airways. 43 individual acini were stereologically analyzed. The stereological characterization is explained in detail in the accompanying publication [2]; briefly, we estimated the acinar surface by counting line probe intersections, the acinar volume by point counting. The number of alveoli was estimated by applying the disector principle to count the new appearance of alveolar entrance rings [7].

Results

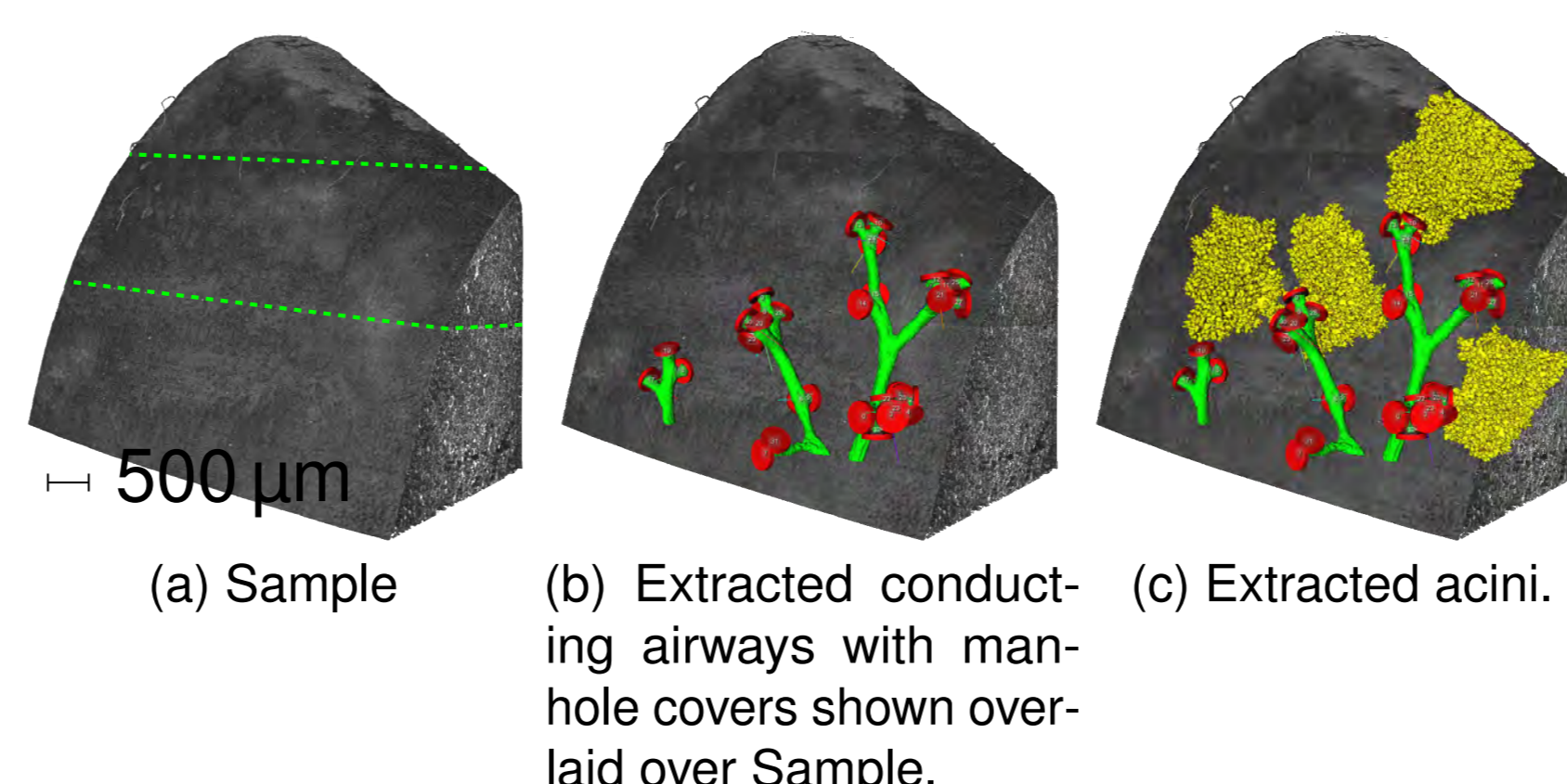


Figure 2: Visualization of the work flow for the extraction of the acinar volumes in a rat lung sample (postnatal day 60): (a): Three-dimensional visualization of the sample. To increase the field of view a stack of three wide field scans were taken. The borders between the three stacked scans are indicated by a dashed green line. (b) Extracted airway segment (green) superimposed on the sample. Using a grey level threshold based region growing algorithm, we extracted conducting airways inside the sample. The red discs (nicknamed manhole covers) were semi-automatically placed and used as segmentation stoppers for the region growing during segmentation of individual acini. (c) Four extracted acini are shown superimposed over the sample in yellow.

Table 1: Summary of results

	Animal 1	Animal 2	Animal 3	Mean	STD
Number of analyzed acini	24	10	9	1.389	1.148
Acinar volume [mm^3]	0.693	1.361	1.389	1.148	0.322
Acinar surface [mm^2]	45.8	69.0	106.9	73.9	25.2
Alveoli per acinus	6505	9330	12750	8470	5979
Total number of acini (surface based)	12145	6914	6865	8641	2478
Total number of acini (alveoli based)	6052	6066	4292	5470	833

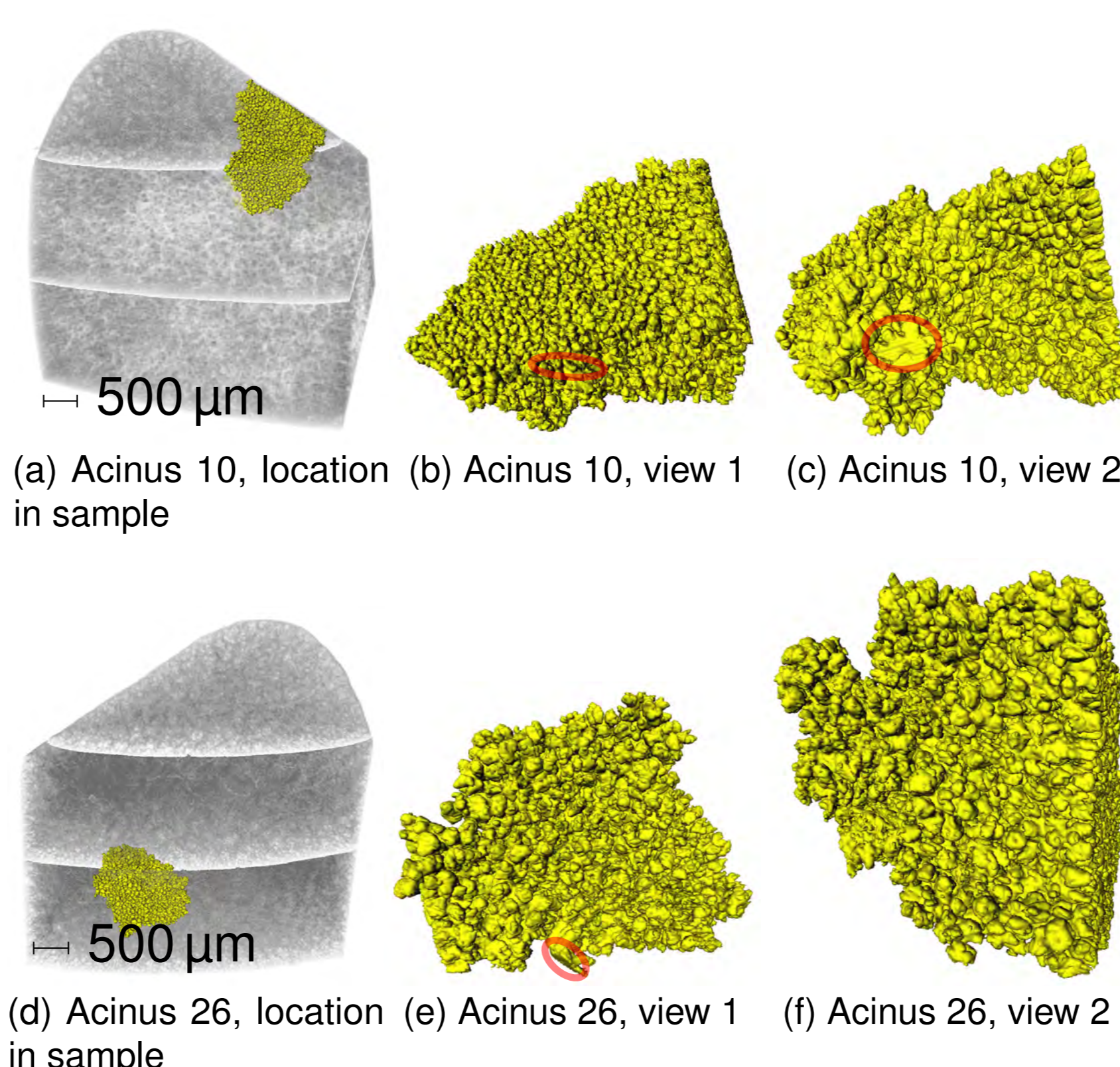


Figure 3: Views of two rat acini. Left: Location of the acinus inside the sample. Middle and right: two different views of each acinus. The red circles mark the approximate position of the segmentation stopper, when visible.

Table 2: Overview of different parameters of rats vs. mice

	Rat	Mouse	Relative Difference [%]
Age [d]	60	"old", 46 to 69, 63, 84 [8, 3, 6, 4]	
Lung volume [mm^3]	10397	1398 [8]	7.44
Mean acinar volume [mm^3]	1.148	0.36, 0.153 and 0.164 [8, 6, 4]	3.19, 7.50 and 7.00
Acinar number	5470	3883 [8]	1.41
Mean alveolar number per acinus	8470	936 [8]	9.05
Mean alveolar volume [μm^3]	88099	59500 [3]	1.48

Conclusion

BOTH acinar volume and mean acinar number match data published for one rat. Rodriguez et al. [5] estimated a mean volume of 1.98 mm^3 and a mean number of acini per lung of 4023 as compared to 1.148 mm^3 and 5470 in our study. Vasilescu et al. [8] performed a micro-tomographic study of mice and found the mean volume of the acini to be 0.36 mm^3 , i. e. a value approximately 3.2 \times smaller than the value we found for our rat lung samples.

We found a mean number of alveoli per acinus in rat of 8470, while [8] found 936, a value approximately 9 \times smaller.

The presented method allows for the nondestructive and semi-automatic extraction of individual acini for stereological analysis of parameters like volume, surface, and number of alveoli per acini, as well as the total number of acini.

We conclude that our novel approach is well suited for the fast and reliable characterization of individual acini in healthy, diseased, or transgenic lungs of different species including humans.

Acknowledgments

THIS work has been supported by the grants 3100A0-109874 and 310030-125397 of the Swiss National Science Foundation. We thank Federica Marone, Christoph Hintermüller and Bernd Pinzer for their committed support at the TOMCAT beamline. Milo Hindennach from Fraunhofer MEVIS provided the segmentation stopper module in MeVisLab. We thank Mohammed Ouanelia and Eveline Yao for expert technical assistance and embedding of the samples.

References

- [1] D. Haberthür, C. Hintermüller, F. Marone, J. C. Schittny, and M. Stampanoni. Radiation dose optimized lateral expansion of the field of view in synchrotron radiation X-ray tomographic microscopy. *Journal of synchrotron radiation*, 17(5):590–9, Sept. 2010. ISSN 1600-5775. doi: 10.1107/S0909049510019618. URL <http://doi.org/10.1107/S0909049510019618>.
- [2] D. Haberthür, S. F. Barré, S. A. Tschanz, E. Yao, M. Stampanoni, and J. C. Schittny. Visualization and stereological characterization of individual rat lung acini by high-resolution X-ray tomographic microscopy. *Journal of Applied Physiology*, pages japphysiol.00642.2013–, Aug. 2013. ISSN 8750-7587. doi: 10.1152/japphysiol.00642.2013. URL <http://dx.doi.org/10.1152/japphysiol.00642.2013>.
- [3] J. Knust, M. Ochs, H. J. r. G. Gundersen, and J. R. Nyengaard. Stereological estimates of alveolar number and size and capillary length and surface area in mice lungs. *Anatomical record (Hoboken, N.J.: 2007)*, 292(1):113–22, Jan. 2009. ISSN 1932-8494. doi: 10.1002/ar.20747. URL <http://doi.org/10.1002/ar.20747>.
- [4] H. Kumar, D. M. Vasilescu, Y. Yin, E. A. Hoffman, M. H. Tawhai, and C.-L. Lin. Multiscale imaging and registration-driven model for pulmonary acinar mechanics in the mouse. *Journal of applied physiology (Bethesda, Md.: 1985)*, 114(8):971–8, Apr. 2013. ISSN 1522-1601. doi: 10.1152/japphysiol.01136.2012. URL <http://doi.org/10.1152/japphysiol.01136.2012>.
- [5] M. Rodriguez, S. Bur, A. Favre, and E. R. Weibel. Pulmonary acinus: geometry and morphometry of the peripheral airway system in rat and rabbit. *The American journal of anatomy*, 180(2):143–55, Oct. 1987. ISSN 0002-9106. doi: 10.1002/aja.1001800204. URL <http://dx.doi.org/10.1002/aja.1001800204>.
- [6] T. Sera, H. Yokota, G. Tanaka, K. Uesugi, N. Yagi, and R. C. Schroter. Murine pulmonary acinar mechanics during quasi-static inflation using synchrotron refraction-enhanced computed tomography. *Journal of applied physiology (Bethesda, Md.: 1985)*, 115(2):219–28, July 2013. ISSN 1522-1601. doi: 10.1152/japphysiol.01105.2012. URL <http://dx.doi.org/10.1152/japphysiol.01105.2012>.
- [7] D. C. Sterio. The unbiased estimation of number and sizes of arbitrary particles using the disector. *Journal of microscopy*, 134(Pt 2):127–36, May 1984. ISSN 0022-2720. URL <http://dx.doi.org/10.1111/j.1365-2818.1984.tb02501.x>.
- [8] D. M. Vasilescu, Z. Gao, P. K. Saha, L. Yin, G. Wang, B. Haefeli-Bleuer, M. Ochs, E. R. Weibel, and E. A. Hoffman. Assessment of morphometry of pulmonary acini in mouse lungs by nondestructive imaging using multiscale microcomputed tomography. *Proceedings of the National Academy of Sciences of the United States of America*, 109(42):17105–10, Oct. 2012. ISSN 1091-6490. doi: 10.1073/pnas.1215112109. URL <http://doi.org/10.1073/pnas.1215112109>.